

Tracking skeletal health in canine skeletal metastatic prostate carcinoma

Leena Park¹, Kristina V. Wells¹, Damian C. Genetos¹

¹Department of Anatomy, Physiology, and Cell Biology, UC Davis School of Veterinary Medicine

Introduction

- Prostate cancer (PCa) is the second leading cause of cancer death in men in the US, with prognosis dramatically decreasing upon metastasis to bone.
- Canine PCa shares important clinical features: spontaneous disease development, age-associated disease and skeletal metastasis
- PCa can subjugate osteoblasts and osteoclasts within bone to form osteoblastic or osteolytic lesions, respectively, and to increase the overall rate of remodeling.
- PCa interactions with osteocytes are unclear.** Because osteocytes regulate osteoblast and osteoclast activity, we sought to understand how PCa cross-talks with osteocytes in a pre-clinical translational canine model.
- In dogs, PCa includes primary adenocarcinomas (PAC) and more commonly, urothelial (transitional cell) carcinomas (UC). Both types of carcinomas metastasize to bone, so both PACs and UCs were included in this study.

Methods

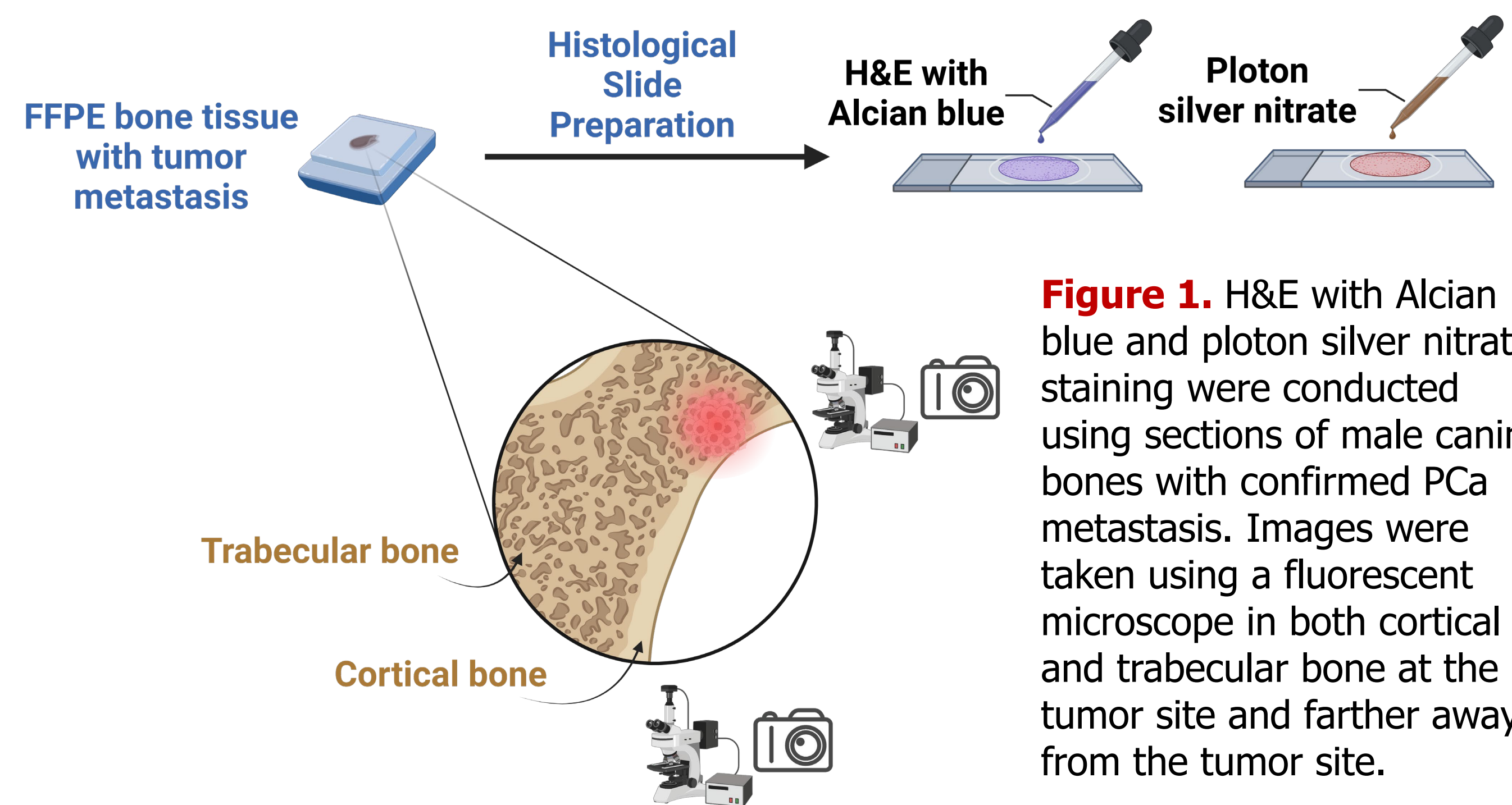


Figure 1. H&E with Alcian blue and ploton silver nitrate staining were conducted using sections of male canine bones with confirmed PCa metastasis. Images were taken using a fluorescent microscope in both cortical and trabecular bone at the tumor site and farther away from the tumor site.

- 129 cases of canine prostate carcinoma (including both PAC and UC) were identified from the UC Davis Veterinary Medical Teaching Hospital from 1988 to 2023
- 9 cases confirmed metastasis to bone
- Histological slides of bone metastases were prepared from 4 cases

Patient ID	Age (years)	Castration Status	Bone Metastasis Site	PAC or UC
46-93-12	10	Castrated	Lumbar vertebrae	UC
48-38-35	13	Castrated	Lumbar vertebrae	UC
72-76-48	8	Intact	Lumbar vertebrae	PAC
36-77-13	8	Castrated	Rib	UC

Table 1. Histological slides were prepared from 4 cases of canine PCa with confirmed metastasis to bone.

Results

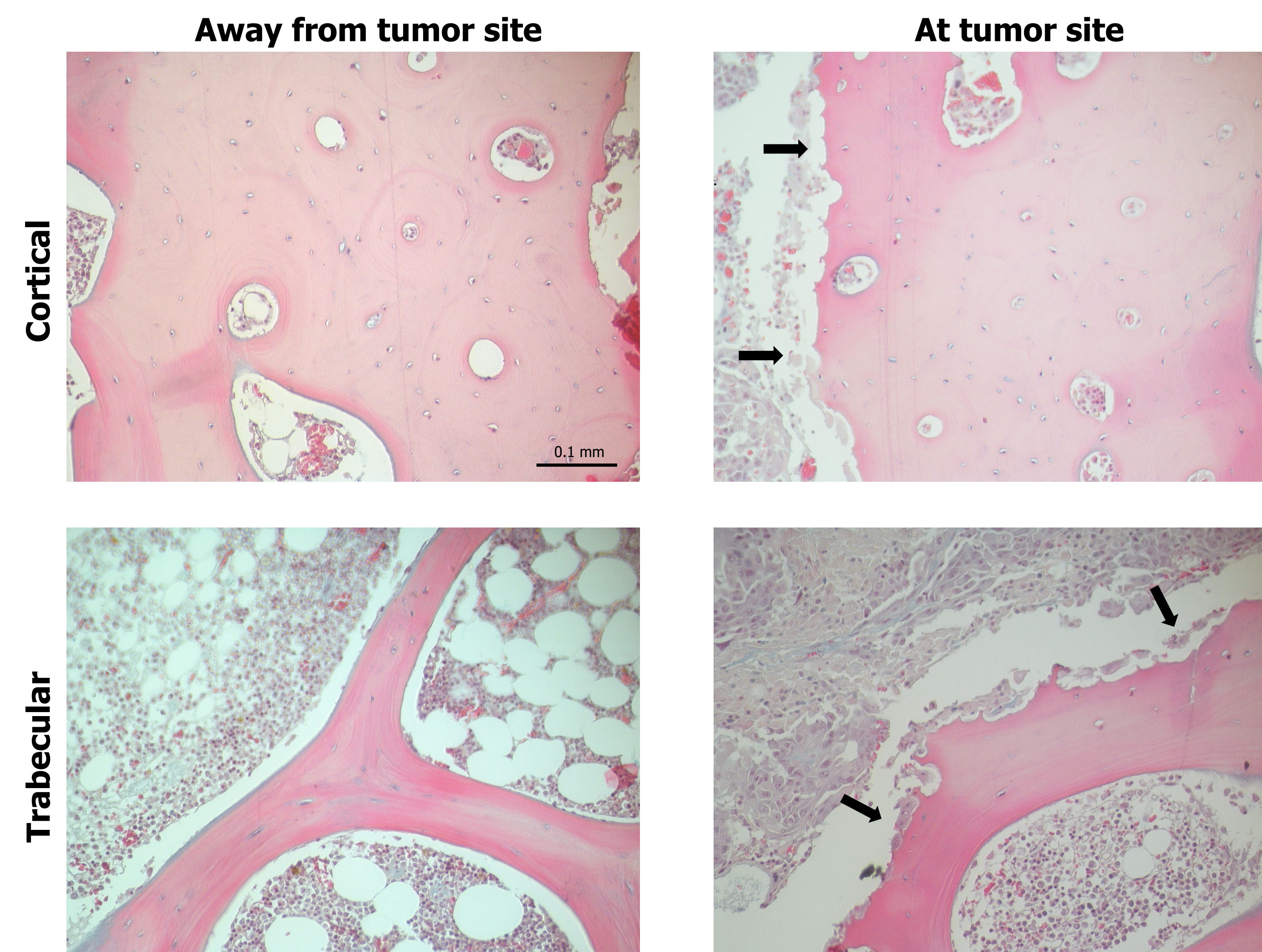


Figure 2. H&E stain. Both cortical and trabecular bone has increased osteolytic lesions (black arrows) closer to the tumor site.

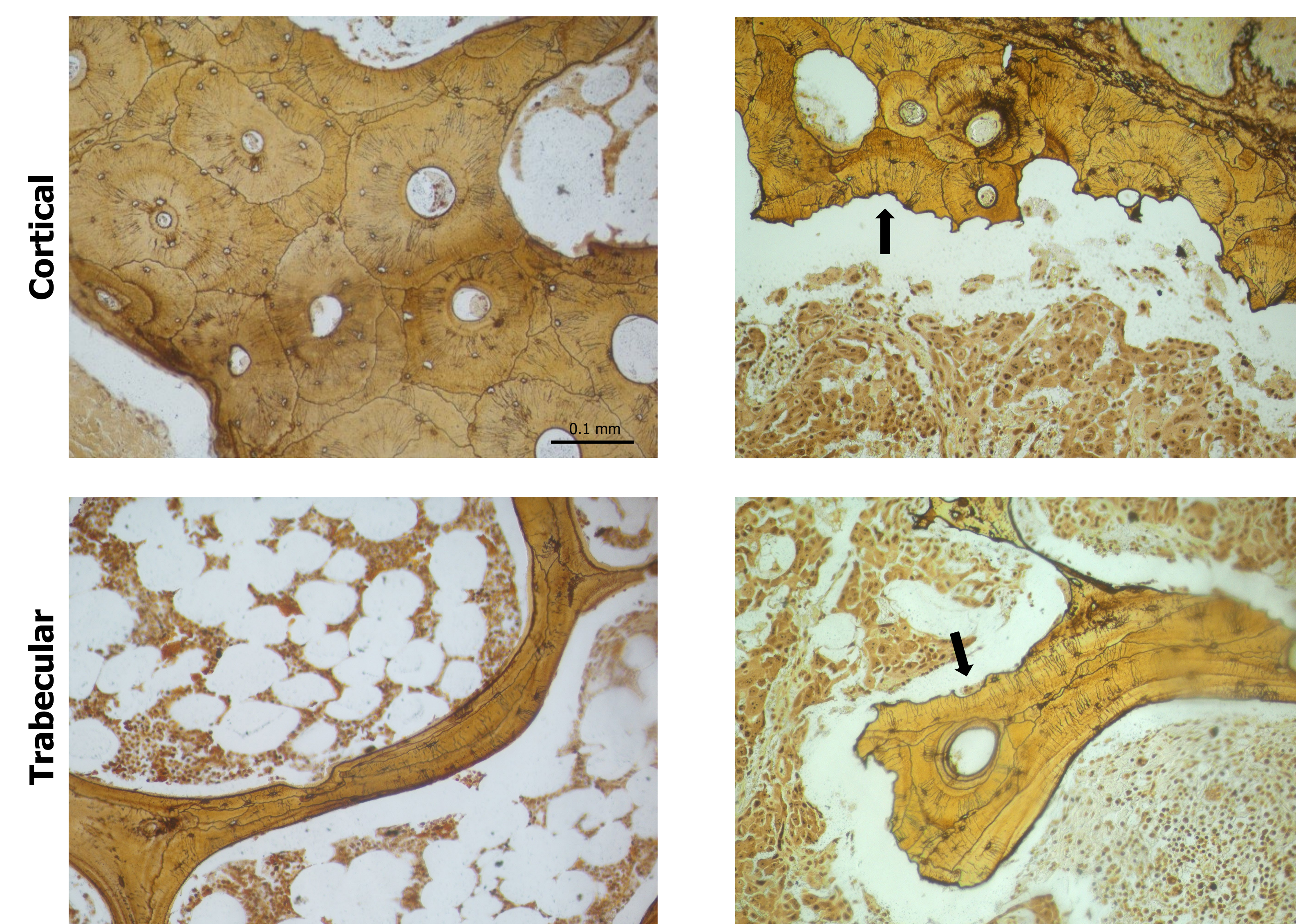


Figure 3. Ploton silver stain. The silver nitrate stain shows increased osteoclast presence (black arrows) and new cement lines closer to the tumor site in both cortical and trabecular bone.

Discussion

- Representative images of the hematoxylin & eosin (H&E) with Alcian blue and ploton silver nitrate staining are shown in **Figures 2 and 3.**
 - H&E with Alcian blue staining showed increased osteoclast activity in both cortical and trabecular bone near the tumor site.
 - Ploton silver staining proved useful in highlighting cement lines and the lacunar-canalicular network to better show bone health.
 - Elevated markers of remodeling (new cement lines, osteoclast presence) was shown clearly in regions near the tumor site.
- Increased osteoclast activity outside of normal lacunar-canalicular bone remodeling seen in both H&E with Alcian blue and ploton silver nitrate stains.**
 - Osteocyte death → unregulated osteoclast function
- Lack of healthy bone did not allow for a comparison to a control group with no metastatic bone disease, so no definitive conclusion can be made.

Future Directions

- Healthy bone can be obtained from the UC Davis VMTH in future male canine necropsies being conducted for reasons unrelated to skeletal health.
 - A matched assessment (castration status, age, bone metastasis site) will allow for comparing osteocyte viability and connectivity in healthy bone vs. bone with metastatic disease.
 - A quantitative assessment of osteocyte dendritic processes will allow for comparing the state of the lacunar-canalicular system in healthy bone vs. bone with metastatic disease.
- Pro-inflammatory cytokines such as CXCL12 and IL1 can be assessed via in situ hybridization to better understand the interaction between PCa and osteocytes.

Acknowledgements

Financial support was provided by the Students Training in Advanced Research (STAR) Program and the NIH T35 Training Grant T35OD010956 (LP), as well as from funding from NIH/NIAMS R01AR073772 (DCG).

References

- Schrank, M. & Romagnoli, S. Prostatic Neoplasia in the intact and castrated dog: How dangerous is castration? *Animals* **10**, 85 (2020).
- Siegel, R.L., Miller, K.D., Wagle, N.S. and Jemal, A. Cancer statistics, 2023. *CA Cancer J Clin* **73**, 27-48 (2023).
- Wong, S. K. *et al.* Prostate cancer and bone metastases: The underlying mechanisms. *International Journal of Molecular Sciences* **20**, 2587 (2019).
- Figure made using Biorender.com