



Gaining Ground on EPM

Disease is very old, and nothing about it has changed. It is we who change, as we learn to recognize what was formerly imperceptible.

— Jean-Martin Charcot (founder of modern neurology, 1825-1893)

Discovery, identification and characterization, diagnostic methods, and treatment. All of these are needed to understand and effectively manage a disease. This inevitably takes time: from years to decades, sometimes hundreds or even thousands of years. Malaria in humans—a disease with similarities to equine protozoal myeloencephalitis (EPM)—has been noted for more than 4,000 years and has influenced human populations and human history to a great extent.

Symptoms of malaria were described in ancient Chinese medical writings from 2700 BC and it became widely recognized in Greece by the 4th century BC. It was responsible for the decline of many of the city-state populations. Hippocrates noted the principal symptoms. By the age of Pericles, there were extensive references to malaria in the literature and depopulation of rural areas was recorded. In the *Susruta*, a Sanskrit



medical treatise, the symptoms of malarial fever were described and attributed to the bites of certain insects. A number of Roman writers attributed malarial diseases to the swamps.

In 1880, a French army surgeon stationed in Algeria, was the first to notice parasites in the blood of a patient suffering from malaria. Subsequently, an Italian neurophysiologist established that there were at least two forms of the disease, one with fever every other day and one with fever every third day. He also observed that the forms produced differing numbers of merozoites (new parasites) upon maturity and that fever coincided

Above photo shows Hallastra, a 22-year-old Arabian mare, the summer after being diagnosed with EPM. She received treatment for approximately 6 months and was rehabilitated with a lot of hand-walking.

INSIDE THIS ISSUE...

Director's Message.....	2
Overview of EPM	3
A Diagnostic Challenge	4
Recent Improvements in Diagnostic Testing.....	4
Other EPM Research at UC Davis	5
Lab Testing for EPM at UC Davis ..	8
Case Studies from the VMTH....	9
Dr. Irwin Liu Retires ..	11

—Continued on page 3



Dr. Gregory L. Ferraro

DIRECTOR'S MESSAGE

Celebrate the Research Successes

Protozoal diseases comprise one of the most difficult areas of study for medical researchers because their modes of

transmission, life cycles for reproduction and modes of infection are not always known. Many of these diseases are impossible to reproduce experimentally, making controlled laboratory research extremely challenging. It is no wonder, then, that several protozoal diseases have been studied for generations, with very little progress toward effective prevention and cure being realized.

The diagnosis of diseases caused by protozoa also can be problematic. Because it may not be possible to ascertain the presence of the parasite in the body, diagnostic tests rely on the detection of antibodies to the parasite produced by the host. While the presence of these antibodies demonstrates exposure, they do not prove either the active presence of the protozoa within the body or that they are the true cause of the physical symptoms of disease observed.

Researchers who choose to study protozoal diseases face monumental intellectual challenges. Only the most dedicated and persistent of individuals tend to excel in this particular area because progress is slow in coming and successful outcomes are rare. Achievements that are realized should therefore be recognized and celebrated by the rest of us.

Equine protozoal myeloencephalitis (EPM) is a disease that typifies the difficulties and challenges I have described and one in which UC Davis researchers have long been involved. Many horses have antibodies to the disease-causing protozoa, but only a few show clinical signs of infection, which can be subtle and easily confused

with those from other causes. The protozoa are extremely difficult to locate within the brain or spinal column of horses that are truly infected. While the life cycle of one of the EPM-causing protozoa, *Sarcocystis neurona*, is known, no one has successfully been able to reproduce the disease in the laboratory.

The Western immunoblot test has been used for a number of years to diagnose EPM. However, the test has had several shortcomings, among which has been that it lacks specificity for diagnosing active EPM infection, providing numerous false-positive results. At best, the test has been useful for ruling out EPM in some cases. Researchers at the UC Davis School of Veterinary Medicine were determined to work on developing a better diagnostic tool and to that end, a five-year investigative effort, funded in large part by the Wayne and Gladys Valley Foundation, recently culminated in a validated, improved diagnostic tool for EPM.

The **SarcoFluor®** and **NeoFluor®** are immunofluorescent antibody tests for both of the known causative agents of EPM, *Sarcocystis neurona* and *Neospora hughesi*. These tests provide a quantitative indication of EPM infection by providing actual titers and a likelihood ratio of disease that correlates with the titer. They also provide greater sensitivity and specificity (i.e., overall accuracy) than the Western immunoblot test and reduce the necessity to obtain cerebrospinal fluid in order to confirm the diagnosis of EPM. The development of these new tests, along with other research accomplishments, are described in this *Horse Report*.

These new diagnostic tools represent a rare and significant success in this most challenging of disease subjects and should be celebrated by all whose horses may be endangered by this disease.

Gaining Ground on EPM —Continued

with the rupture and release of merozoites into the bloodstream. In the 1890s, the malaria parasites were named, and it was first demonstrated that a mosquito could transmit a (bird) malaria parasite.

By comparison, the work accomplished since 1970, when the first description of EPM was published, has occurred with lightning speed. Dr. Martin Furr of the Virginia-Maryland Regional College of Veterinary Medicine described this work as follows:

The EPM story is truly a success story for modern veterinary research. Twenty-five years ago we became aware of an enigmatic parasitic infection of the nervous system of the horse. Since then, veterinary and affiliated scientists have determined the cause of the illness, worked out a complicated life cycle, described the epidemiology of the disease, developed specific tests to diagnose infection, and developed pharmaceutical agents to treat the infection. This highlights the importance of research in all aspects of an illness, and research's contribution toward the final goal of effective means of prevention or treatment in individual animals.

In research, an idea that initially shows promise all too often does not work out. So we start over again, trial and error. Sometimes we don't even have the right problem. Einstein once said, "If we knew exactly what we were

doing it would not be called research, would it?"

So despite the progress made to date in our understanding of EPM, it has been and continues to be one of the more challenging problems in modern equine veterinary medicine. The ability to diagnose and treat the disease is far from perfect, and research to improve the outcome of horses affected with EPM continues at a number of institutions around the country, including UC Davis.

Overview of EPM

EPM is caused by infection of the central nervous system of horses and ponies with the protozoan parasites *Sarcocystis neurona* and, less commonly, *Neospora* spp., particularly *Neospora hughesi*. It is often a progressively debilitating disease affecting anywhere from the front part of the cerebrum to the end of the spinal cord. Clinical signs are dependent on the area of the central nervous system that is parasitized. Spinal cord involvement can manifest in gait abnormalities, incoordination,

ataxia (inability to control voluntary muscle movement), spasticity in all four limbs, and muscle atrophy, whereas brain stem involvement may manifest in depression, behavioral changes, and cranial nerve paralysis (facial nerve paralysis, tongue paralysis, difficulty swallowing).

EPM is considered to be the most prevalent cause of neurologic disease of horses in the Americas. Over 30% of horses in some parts of the United States have antibodies to *S. neurona*, although a much smaller percentage of exposed horses develop clinical EPM, indicating that additional factors, which we do not yet understand, also contribute to the onset of this disease (Njoku et al., 2002).

The geographic range of clinical EPM in horses is defined by the range of the opossum, the definitive host of *S. neurona*. In areas where the opossum is common, approximately 50% of horses are seropositive,

—Continued on page 4



Gaining Ground on EPM —Continued

indicating exposure to the organism. In central Wyoming and Montana, outside the natural range of opossums, only 6.5% and 0%, respectively, of wild horses were seropositive for *S. neurona*. In South America, the opossum is also a definitive host for *S. neurona*, with approximately 35% of horses in Brazil and Argentina shown to be seropositive (Sellon and Dubey, 2007).

A few cases of EPM are associated with *N. hughesi*, another protozoal parasite. The natural host(s) of this organism has not yet been identified, though we do know that the dog is the definitive host for the closely related *Neospora caninum*. Cases of EPM due to *N. hughesi* can have a wide range of symptoms, including hind limb ataxia and hind limb weakness that progresses to more generalized weakness and recumbency. Clinicians at UC Davis have noticed mainly gait abnormalities and ataxia, and that cases diagnosed with EPM due to neosporosis often have concurrent diseases (polysaccharide storage myopathy or other viral infections known to cause ataxia).

A Diagnostic Challenge

At the forefront of the challenges presented by EPM has been the availability of a reliable, definitive diagnostic test. Because horses with EPM can have a variety of differing clinical signs, and because 30% to 60% of horses in North America have antibodies to the primary

protozoal parasite responsible for EPM, *Sarcocystis neurona*, EPM is inherently difficult to diagnose. At the present time, definitive diagnosis of EPM relies on postmortem examination of neural tissue. No test in the live horse is currently considered definitive. Therefore, EPM is diagnosed based on a combination of (1) a thorough neurologic examination, (2) evaluation of serum and/or cerebrospinal fluid for the presence of antibodies to *S. neurona* and/or *N. hughesi*, and (3) the elimination of other neurological disorders (Finno et al., 2007).

Until very recently, the primary diagnostic test used to determine EPM infection has been the Western immunoblot test, which is based on the detection of *S. neurona*-specific antibodies in the blood and/or cerebrospinal fluid (CSF). However, the test has several shortcomings that limit the usefulness of the information it provides:

- (1) It detects the presence of *S. neurona*-specific antibodies in the serum or CSF, but approximately 30% to 60% of clinically normal horses in many parts of the United States have antibodies to *S. neurona* without having EPM.
- (2) Contamination of cerebrospinal fluid with even minute quantities of peripheral blood (equivalent to 8 cells per μL of fluid) can produce a false-positive result if the horse has antibodies in the blood.

Consequently, the primary value of the Western immunoblot test has been in *ruling out* EPM

caused by sarcocysts in horses when the prevalence of infection is low or moderate (Sellon and Dubey, 2007).

Recent Improvements in Diagnostic Testing

In the past decade, researchers at UC Davis have undertaken a study to compare the overall accuracy of an indirect fluorescent antibody test (IFAT) with the Western immunoblot test and an improved version of it (modified Western immunoblot test) for diagnosing EPM. The modified Western immunoblot test was reported to produce fewer false-positive results (Duarte et al., 2003). After researching and testing a number of potential options for improving the IFAT, the UC Davis team has been able to demonstrate that the overall accuracy of the improved IFAT is better than that of the two Western immunoblot tests and it can detect *Neospora hughesi*, which the Western immunoblot cannot.

These new tests have been designated **SarcoFluor**[®] for *S. neurona* and **NeoFluor**[®] for *N. hughesi*. They provide a quantitative result so that the titer is associated with a calculated probability of disease, giving clinicians more information to work with in determining treatment. The tests have been validated at UC Davis using gold-standard sera from known naturally infected horses (confirmed at necropsy by immunohistochemical identification of parasites in neural tissues) and with sera from horses experimentally infected with *N. hughesi* (Packham et al., 2002; Duarte et al., 2006).

When tested with serum samples, the **SarcoFluor®** IFAT was more accurate than the Western immunoblot test for diagnosing *S. neurona* EPM. With cerebrospinal fluid, the test's sensitivity and specificity (i.e., overall accuracy) were 100% and 99%, respectively (1:5 titer cutoff).

The **NeoFluor®** IFAT is currently the only test available for detecting antibodies to *N. hughesi*.

Compared with the Western immunoblot test, the **SarcoFluor®** offers the following advantages for diagnosing EPM caused by *S. neurona*:

- Increased sensitivity and specificity for identifying infected horses.
- Results (expressed as titer values) are truly quantitative, thereby allowing improved interpretation of the likelihood of active EPM infection and disease rather than simply an indication of exposure. The higher the IFAT antibody titer, the more likely that EPM is the cause of the horse's neurologic signs.
- Less sensitive to blood contamination of cerebrospinal fluid (as high as 10,000 RBC/ μ L), resulting in fewer false-positive results.
- Reduced necessity to perform cerebrospinal fluid collection in order to confirm a diagnosis of EPM. The likelihood of EPM is sufficiently high in horses with high titers of antibody in blood that cerebrospinal fluid analysis may not be necessary.

- Tests are faster to perform, less expensive and less labor-intensive.

Because the **SarcoFluor®** and **NeoFluor®** tests are based on the detection of antibodies to the respective parasites rather than on detection of the parasites themselves, they suffer the shortcomings inherent in all such antibody-based tests for confirmation of EPM. Nonetheless, the increased sensitivity and specificity of the procedures combined with their quantitative nature offer significant advantages over conventional Western immunoblot testing.

Moreover, the diagnosis of EPM often involves a cerebrospinal fluid (CSF) tap, which frequently results in blood contamination of the fluid during the collection procedure and leads to false-positive results in the Western immunoblot test with as few as 8 RBC/ μ L of CSF. Studies have demonstrated that the **SarcoFluor®** and **NeoFluor®** tests are reliable for testing horses for EPM even when blood contamination causes the RBC concentration in CSF to be as high as 10,000 RBC/ μ L. This results in fewer false-positive readings (Finno et al., 2007).

Dr. Carrie Finno of the William R. Pritchard Veterinary Medical Teaching Hospital at UC Davis has been involved in studies to further validate the **SarcoFluor®** and **NeoFluor®** tests. After a considerable amount of investigation and research, she summarizes the tests as follows:

As a clinician, I appreciate having an actual titer attached to

*a serologic result and a likelihood ratio of disease that correlates with the titer. [With the Western immunoblot test, the results are read qualitatively as negative, weakly immunoreactive, moderately immunoreactive, or strongly immunoreactive.] In the case of EPM due to *N. hughesi*, the indirect fluorescent antibody test is the only validated available antemortem (in the living horse) test. I think clinicians who elect to use the Western immunoblot test may be missing cases of EPM due to *N. hughesi*. I have colleagues in the Midwest who began to use the IFAT from UC Davis and have picked up cases of *N. hughesi* in their region.*

Also, as the resident who completed the cerebrospinal fluid contamination study [with the IFAT], I was considerably impressed with the amount of red blood cell contamination that it took to create a false positive test result on CSF with the IFAT test. As our lumbosacral taps are very rarely completely "clean" (i.e., free of blood contamination, with <1 RBC/ μ L), this information is particularly useful in helping veterinarians interpret IFAT results on contaminated cerebrospinal fluid.

More information on the **SarcoFluor®** and **NeoFluor®** tests offered by UC Davis is provided on page 8 of this *Horse Report*.

Other EPM Research at UC Davis

While most clinical cases of EPM are caused by *S. neurona*, a few cases are due to infection with *N. hughesi*, for which we have less

—Continued on page 6

Gaining Ground on EPM

—Continued

information. The life cycle of *N. hughesi* is as yet uncharacterized, but we believe that it may have some similarity to the closely related *Neospora caninum*. However, there is no conclusive evidence that dogs can transmit *N. hughesi* to horses.

The definitive host for *N. caninum*—the dog—ingests material containing *N. caninum* tissue cysts and becomes infected with the parasite. Sexual multiplication takes place in the intestine of the definitive host and oocysts are produced. *N. caninum* oocysts are excreted with the feces of the definitive host. Cattle, which are intermediate hosts, become infected by ingesting food contaminated by infected dog feces containing *N. caninum* oocysts. In the gut, sporozoites are released from the oocysts and penetrate the epithelium of the small intestine. The sporozoites then enter different tissues but are mostly found in the reticuloendothelial system. Here, they further differentiate into tachyzoites. Tachyzoites reproduce rapidly asexually and invade different tissues, including the fetus via the placenta in pregnant animals.

With the onset of the bovine immune response, tachyzoites revert to dormant bradyzoites within tissue cysts (found mainly in neural tissue). During future pregnancies in infected animals, bradyzoites are reactivated and differentiate into tachyzoites that invade the fetus via the placenta. The congenital route of transfer of *N. caninum* is the main transmission route in cattle. Although abortion can occur after tachyzoites infect the fetus, many calves are born with no clinical sign of neosporosis. These calves can transmit the parasite to their offspring.

The EPM research group at UC Davis has determined that *N. hughesi* is likely transmitted vertically in horses. As in cattle, the parasite invades different tissues, including the fetus via the placenta. Preliminary results from our studies have shown that persistently infected broodmares give birth to healthy foals that have evidence of intrauterine infection, as evidenced by *N. hughesi* antibodies in their blood prior to ingestion of colostrum. These mares harbor the pathogen, which is dormant most of the time and becomes active during late gestation, crossing the uteroplacental unit. Following gestation, the pathogen becomes dormant again.

We are currently following two mares and six offspring, all of whom are healthy. One foal showed ataxia at 4 months of age but improved with antiprotozoal treatment and is currently doing well. These investigations are ongoing. ✱

Let us keep looking in spite of everything. Let us keep searching. It is indeed the best method of finding, and perhaps thanks to our efforts, the verdict we will give such a patient tomorrow will not be the same we must give this man today. – Jean-Martin Charcot

Acknowledgments

Special thanks to Dr. David Wilson, Dr. Nicola Pusterla, Dr. Carrie Finno and Dr. John Madigan of the William R. Pritchard Veterinary Medical Teaching Hospital, UC Davis School of Veterinary Medicine, for their contributions to this article. Thanks also to Dr. Gary Magdesian and Dr. Monica Aleman for contributing case studies for this *Horse Report*.

References

Sellon, Debra C., and J. P. Dubey. Equine Protozoal Myeloencephalitis. *In* Equine Infectious Diseases (Debra Sellon and Maureen Long, Eds.), Chapter 59, Elsevier Saunders, 2007.



One of the mares and foals being followed in a UC Davis study of vertical transmission of the protozoal parasite *Neospora hughesi*.

Njoku, Chinedu J., William J. A. Saville, Stephen M. Reed, et al. Reduced levels of nitric oxide metabolites in cerebrospinal fluid are associated with equine protozoal myeloencephalitis. *Clinical and Diagnostic Laboratory Immunology* 9(3), 605-610, May 2002.

Duarte, P. C., B. M. Daft, P. A. Conrad, et al. Evaluation and comparison of an indirect fluorescent antibody test for detection of antibodies to *Sarcocystis neurona*, using serum and cerebrospinal fluid of naturally and experimentally infected, and vaccinated horses. *Journal of Parasitology* 90(2), 379-386, April 2004.

Duarte, P. C., B. M. Daft, P. A. Conrad, A. E. Packham, and I. A. Gardner. Comparison of a serum indirect fluorescent antibody test with two Western blot tests for the diagnosis of equine protozoal myeloencephalitis. *Journal of Veterinary Diagnostic Investigation* 15(1), 8-13, January 2003.

Duarte, P. C., E. D. Ebel, J. Traub-Dargatz, et al. Indirect fluorescent antibody testing of cerebrospinal fluid for diagnosis of EPM. *American Journal of Veterinary Research* 65(5), 869-876, 2006.

Packham, A., P. Conrad, W. Wilson, et al. Qualitative evaluation of selective tests for detection of *N. hughesi* antibodies in serum and cerebrospinal fluid of experimentally infected horses. *Journal of Parasitology* 88(6), 1239-1246, 2002.

Finno, C. J., A. E. Packham, D. Wilson, I. A. Gardner, P. A. Conrad, and N. Pusterla. Effects of blood contamination of cerebrospinal fluid on results of indirect fluorescent antibody tests for detection of antibodies against *Sarcocystis neurona* and *Neospora hughesi*. *Journal of Veterinary Diagnostic Investigation* 19(3), 286-289, 2007.

Furr, Martin. Effective Prevention Needed for EPM. Equine Research Coordination Group White Paper, January 2009, www.aaep.org/equine_research_co_group.htm.

Laboratory Testing for EPM at the William R. Pritchard Veterinary Medical Teaching Hospital

The UC Davis Veterinary Medical Teaching Hospital currently offers the following laboratory tests for EPM on serum and cerebrospinal fluid (CSF) samples:

- **SarcoFluor®** indirect fluorescent antibody test (IFAT) for antibodies to *Sarcocystis neurona*
- **NeoFluor®** indirect fluorescent antibody test (IFAT) for antibodies to *Neospora hughesi*
- Western immunoblot antibody titer for antibodies to *S. neurona*

Both the **SarcoFluor®** and **NeoFluor®** tests can be ordered on the same sample as an IFAT EPM panel (the preferred approach) or the tests can be ordered separately.

While our primary goal is to make these improved diagnostic tests available to practicing veterinarians in order to enhance their ability to rule out EPM or provide a definitive diagnosis of EPM, we also take seriously our obligation to continually refine test validation by adding new data from field cases. We, therefore, request that you do the following:

1. Confirm that the horse from which the samples were collected has neurological signs consistent with EPM.
2. Provide an appropriate history and summary of findings of the neurological examination.
3. Provide a summary of results of tests to rule out other differential diagnostic considerations such as compressive myelopathy and West Nile virus infection.
4. Confirm that the horse from which the samples were collected has no history of vaccination against EPM.
5. When samples of both serum and CSF are collected from the same horse, please submit them concurrently.

All samples must be sent packed with an icepack by overnight delivery. Samples are received only during normal business hours (Monday through Friday, 8:00 AM to 5:00 PM); therefore, they should not be sent on a Friday or on a weekend or public holiday. Turnaround times for the **SarcoFluor®** and **NeoFluor®** tests are 5 to 7 business days from sample receipt, and 1 to 2 weeks for the Western immunoblot test.

Submission forms must accompany samples and may be found on the following website:

www.vetmed.ucdavis.edu/vmth/small_animal/laboratory/factsheets.cfm

Contact information for the laboratory:

Immunology/Virology Laboratory

William R. Pritchard Veterinary Medical Teaching Hospital

Telephone: (530) 752-7373

Fax: (530) 754-9007

E-mail: **ettrevino@vmth.ucdavis.edu**, or **hbwiese@vmth.ucdavis.edu**

A Case Study from the William R. Pritchard Veterinary Medical Teaching Hospital, UC Davis

A Tribute to Hallastra

Hallastra was a 20-year-old Arabian mare that was presented to the VMTH with progressive stumbling, leaning to the left, and circling. She had been used as an endurance trail horse. She was last ridden 3 weeks prior, during which time she seemed normal.

On physical examination, the mare was found to be slightly lethargic and to have reduced muscle mass. A neurological examination performed by Dr. Gary Magdesian and Dr. John Madigan revealed marked and compulsive circling to the left, severe leaning to the left, and a right-sided head tilt and facial nerve paresis. The mare seemed unbalanced and unsteady on her feet.

Based on the results of the neurological examination, the diagnosis was paradoxical vestibular syndrome, a problem of the brainstem and cerebellum, parts of the brain that control balance and motor function, as well as housing the origin of the facial nerve. The causes of vestibular disease in horses include otitis interna-media, temporohyoid osteoarthropathy, equine protozoal myeloencephalitis, brainstem abscess, aberrant parasite migration, trauma, neoplasm, herpes virus, rabies and West Nile virus infections, and metabolic diseases (hepatic encephalopathy or uremic encephalopathy).

Diagnostics included cranial radiography, complete blood panel (CBC and chemistry panel), cerebrospinal fluid tap, serology for herpes, guttural pouch endoscopy, and western blot analysis of blood and cerebrospinal fluid for EPM testing. The x-rays were unremarkable, showing no signs of trauma. Guttural pouch endoscopy was not consistent with temporohyoid osteoarthropathy or trauma. The blood work was normal, ruling out metabolic causes for the disease. The cerebrospinal had normal white blood cell and protein count, but there was an increase in the percentage of inflammatory cells indicative of inflammation. The serology for herpes infection was negative. The western blot titers, in both serum and cerebrospinal fluid, were both strongly positive for *Sarcocystis neurona*.

While the serum western blot results could represent either exposure or true infection, the positive result in a clean tap (free of blood contamination) of the cerebrospinal fluid was indicative of a true infection. Hallastra was treated with trimethoprim sulfamethoxazole and pyrimethamine, both targeting the EPM organisms. Within about 2 weeks, the mare began showing some improvement and gradually improved over the next several months. She was treated with this drug combination for approximately 6 months.

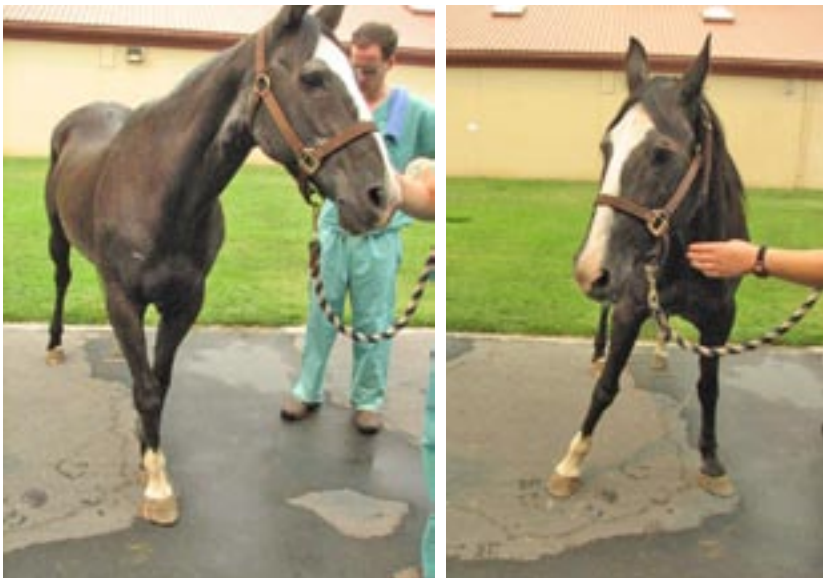Hallastra was rehabilitated with a lot of hand-walking and ponying off of another horse. During her convalescence, she was also treated with acupuncture. Nine months after her diagnosis, Hallastra was being ridden on trail again. Except for some mild weakness of the right front leg, she was back to her old self.

A Case Study from the William R. Pritchard Veterinary Medical Teaching Hospital, UC Davis

Misty: A Case of *Neospora hughesi*

Misty was a 29-year-old Quarter horse mare that presented with a 2-month history of progressive pelvic limb lameness. Misty was seen by the clinicians at the UC Davis Veterinary Medical Teaching Hospital, and her physical examination revealed diffuse but asymmetric muscle atrophy over multiple areas.

Misty's neurological status was abnormal and included head tilt, unilateral facial paresis, bilateral decreased skin sensation over the entire body, incoordination, and a gait that ranged from hypometric (decreased range of motion) to hypermetric (exaggerated range of motion).



Misty when she presented to the UC Davis Veterinary Medical Teaching Hospital. Note the abnormal feet placement (abnormal proprioception).

Misty also had a series of diagnostic tests to rule out potential health issues. A blood serum test for EPM using the new indirect fluorescent antibody test (**NeoFluor**®) revealed one of the highest titers for *Neospora hughesi* that we have ever seen at our laboratory from samples from our horse population as well as from outside samples, including other states.

The mare's neurological deficits were in various anatomical regions but were worse in the pelvic limbs, such that she could easily fall to the ground and have difficulty getting up. She was treated with a 2-month course of an oral antiprotozoal drug. Her last examination in October 2008 showed much improvement of her neurological deficits, although some mild to moderate problems remained.



CEH Horse Report Recognized by American Horse Publications

The *Horse Report* received a first-place award for *Best Equine-Related Newsletter* by American Horse Publications. The award was for material published in 2008. The award was announced at the annual American Horse Publications Seminar in an awards ceremony held June 27, 2009, in New Orleans, LA.

Two issues of the *Horse Report*—*Stem Cells and Regenerative Medicine in Horses* and *Colic: An Age-Old Disease*—received the award. American Horse Publications provides members with an opportunity to be recognized for excellence in equine publishing as well as receive professional critiques for improvement.

Dr. Irwin Liu, Distinguished Professor of Equine Reproduction, Retires

Retirement is wonderful. It's doing nothing without worrying about getting caught at it.

Dr. Irwin Liu, a good friend and colleague to many of us here at the School of Veterinary Medicine, has recently elected to retire from UC Davis where he has had a long and illustrious career, beginning as a student in 1968.

He first received a Master's degree here in preventive veterinary medicine, followed by a postdoctoral fellowship, an internship (equine reproduction) and residency (large animal medicine), culminating in a teaching position as a lecturer. This began his long academic career as a professor of equine reproduction, which he sustained until his recent retirement.

As a distinguished professor of theriogenology for several decades, the quality and significance of Dr. Liu's research has been recognized worldwide.

As a teacher, his advice, council and mentorship have provided a sound foundation to several generations of veterinarians seeking careers in equine reproduction.

The skillful application of his clinical talents and advice on behalf of horse breeders and farm owners has constantly proven invaluable. He has long been an expert horseman whose enthusiasm and dedication to the equine industry has never wavered.

His ever-present positive influence on our veterinary school will be genuinely missed by all—humans and equines alike. We wish Dr. Liu well in his retirement!



In 2007, Dr. Irwin Liu (shown on right) was selected as the recipient of the 2007 Bartlett Award by the Society for Theriogenology and the American College of Theriogenologists. Dr. Patrick Hearn presented the award to Dr. Liu.


CEH
HORSEREPORT

Mail ID#1415
Center for Equine Health
School of Veterinary Medicine
University of California
One Shields Avenue
Davis, CA 95616-8589

Nonprofit Org.
U.S. POSTAGE
PAID
UC Davis

RETURN SERVICE REQUESTED

VISIT OUR WEB SITE . . .



www.vetmed.ucdavis.edu/ceh

If you are accessing *The Horse Report* from our website and no longer want a paper copy, **PLEASE LET US KNOW** save us the postage; the horses will benefit!

Send an e-mail request to
ljchristison@ucdavis.edu

CEH
HORSEREPORT

©The Regents of the
University of California
July 2009

Center for Equine Health
(530) 752-6433
www.vetmed.ucdavis.edu/ceh

Director:
Dr. Gregory L. Ferraro
E-mail: glferraro@ucdavis.edu

Senior Editor:
Barbara Meierhenry
E-mail: cehwriter@ucdavis.edu

Management Services Officer:
Katie Glide
E-mail: kaglide@ucdavis.edu

Dean, School of Veterinary Medicine:
Dr. Bennie I. Osburn

The Center for Equine Health is supported with funds provided by the State of California Pari-Mutuel Fund and contributions by private donors.

The University of California does not discriminate in any of its policies, procedures or practices.

The University is an affirmative action/equal opportunity employer. The information you provide will be used for University business and will not be released unless required by law. To review your record, contact Advancement Services, 1480 Drew Avenue, Ste. 130, Davis, CA 95616. A portion of all gifts is used to defray the costs of administering the funds. All gifts are tax-deductible as prescribed by law.