

HEARTBEAT

UC DAVIS VETERINARY HOSPITAL

VOL. 6, 2018

Special Edition



UCDAVIS

VETERINARY MEDICINE

Veterinary Medical Teaching Hospital



Looking to the Future

If you've driven by the veterinary hospital over the past few months, you will have noticed the initial construction projects for Phase I of our new Veterinary Medical Center (VMC). When I see the progress made on a daily basis, I am excited to envision our future campus—the foremost state-of-the-art veterinary center in the country. It is such an exciting time to be a part of this UC Davis team of professionals who are leading the way toward a healthier future for animals.

Our new VMC will ensure full access to the best possible care options for your animals' needs. Our unique and comprehensive VMC will combine compassionate health care for animals with innovation, discovery and education.

Your patient and client experience will be at the heart of our new center. With immediate access to innovative technologies and services with modern facilities, our faculty, staff and students will work as an integrated team to deliver the most effective treatment plans for your animals.

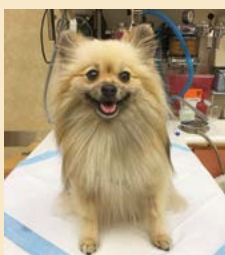The university recently unveiled its new strategic plan. Chancellor May has entitled it "To Boldly Go." How fitting a vision, as our bold approach to the future of veterinary medicine begins to unfold. Thank you for coming with us on this journey. We hope you are as excited as we are to see it through to its historic culmination. While that will take a decade, together we will make it happen. Remember, we cannot achieve this without your support. We look forward to continuing that relationship with you.

Warmest regards,

Dr. Jane Sykes
Chief Veterinary Medical Officer

On the Front Cover

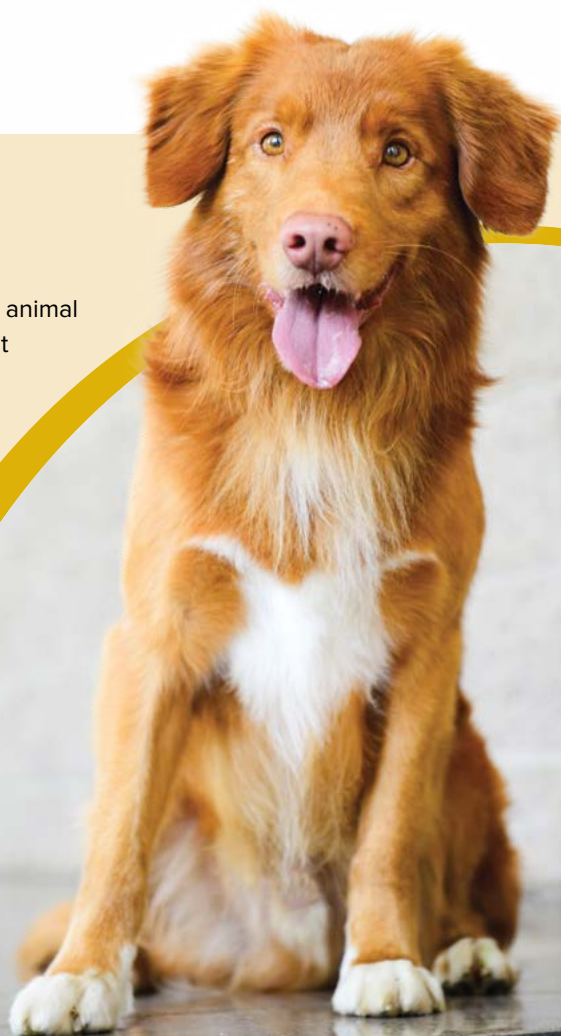While the UC Davis veterinary hospital treats just about any kind of species of animal you could imagine, 68 percent of our patients are like me—a dog! Since I don't have thumbs to help me pick things up, I rely on my mouth to do all sorts of things. It's so important that dogs have healthy mouths. That's why I'm excited to see this issue of *Heartbeat* focusing on the Dentistry and Oral Surgery Service.



Pictured on the front cover is my friend, Puff. She was a recent patient of the dentistry team after her owners discovered a cracked tooth.

Unfortunately, Puff's tooth had to be extracted, but now she has a healthy mouth once again. The veterinarians even gave Puff's owners a long-term plan to keep

her teeth and gums in top shape. To read more about the Dentistry and Oral Surgery Service, please see page 4.



A Special Room Honoring a Special Veterinarian

Grateful clients Bob and Colleen Haas appreciate the decades of exceptional care their veterinarian and friend, the late Dr. Paul Miller ('71), provided for their horses. To honor him, the Haases contributed a gift to name the Paul Miller Rounds Room in the Equine Performance Center (EPC), envisioned as part of the master plan for the new UC Davis Veterinary Medical Center.

"Paul exemplified the best of UC Davis veterinary medicine," said Colleen. "His brilliance, expertise and compassion as an extraordinary veterinarian were equally matched by his human kindness. His care of our horses over many years and the privilege of knowing him were gifts that we will treasure forever."

Dr. Miller practiced large animal medicine in Siskiyou County since the 1970s. Well-known and respected, he loved the area's open land as much as he loved the animals and clients he served.



Portrait of Dr. Paul Miller, remembered for his dedicated care of horses

Among Dr. Miller's greatest strengths were his excellent communication and collaboration skills. A fitting tribute, the Paul Miller Rounds Room will provide a space designed to foster these skills. Veterinarians, students and staff will be able to come together to discuss cases and consider the latest treatment options, supporting the highest quality of equine care and helping train future veterinarians.

To ensure that exceptional care continues well into the future, the EPC will include a new arena and gait analysis capability for lameness evaluations. The facility design includes state-of-the-art force-plate and video analysis, not available in many veterinary settings, and opens a new avenue to improved performance through

the application of clinical research. For more information, visit www.vetmed.ucdavis.edu/giving/vmc.

If you would like to honor someone special through a naming opportunity, please contact our Advancement team at 530-752-7024.

A Passion for Parakeets

Idele Gilbert, known as the "bird whisperer" by her friends, enjoys a special bond with her parakeet, Jesse. She describes him as the smartest avian companion she has had. A quick learner, Jesse began to talk with just one week of training and to twirl around on his perch after watching a dancing show on television.

Including Jesse, Idele has owned 13 pet parakeets over the years—a passion that began when she was a child. She has only owned one bird at a time and acquired all of them when they were 6-8 weeks old. Idele soon earned their trust by spending time with them daily and established close bonds with each.

With their cheerful disposition and affectionate nature, parakeets have found a special place in the hearts of Idele and her husband, Harry. Their love for these birds inspired them to

include the school in their estate planning to support research to advance avian medicine and to create an endowed scholarship for students with an interest in avian companion animals.

"My parakeets have been like children to me," said Idele. "Each one has had a unique personality and brought me a lot of joy. I'm so happy to have known each of these little darlings, but miss them dearly. I hope that our gift will help companion birds like ours enjoy healthier and longer lives."

If you have a love for birds—or other companion animals—and want to make a difference in improving their health, please contact our Advancement team at 530-752-7024.



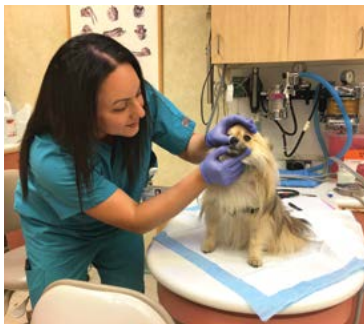Idele and Harry Gilbert's love for animals has also sparked their interest in hobbies. Idele holds a parakeet, modelled after Jesse, that she created using tiny beads. Pictured behind them are some of their collectible plush animals.

Taking Dental and Oral Health to Uncharted Territories

When Lilly first visited the UC Davis veterinary hospital in 2006 for evaluation of her chronic mouth problem, known as feline gingivostomatitis (FCGS), no one knew that a potential resolution to her painful disease was going to come to light six years later. And in the subsequent six years, the hospital's Dentistry and Oral Surgery Service (DOSS) has continued to develop groundbreaking applications and procedures. Led by faculty members Drs. Frank Verstraete and Boaz Arzi, the service is the most advanced veterinary dental and oral surgery team of any academic center in the country.

Day after day, DOSS patients benefit from the advanced level of care offered by the faculty and their team of caregivers. Collaborations with other specialists throughout the hospital, as well as with other campus entities such as the Veterinary Institute of Regenerative Cures (VIRC), the Department of Biomedical Engineering (BME) and the School of Medicine, continue to improve the level of care offered.

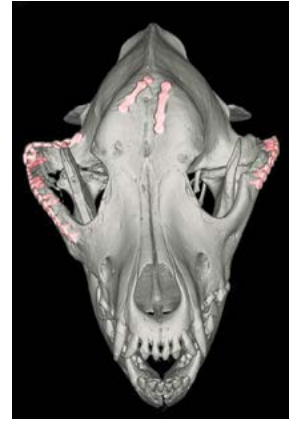
DOSS faculty seek to improve understanding of oral disease processes, to expand upon available treatment options, and to optimize patient care. A full range of dental and surgical services is available for dogs, cats, horses, pet rabbits and rodents, and zoo animals. The team's extensive expertise and reputation in dentistry, oral and maxillofacial surgery attracts patients from all over California, as well as a number of other states and countries.



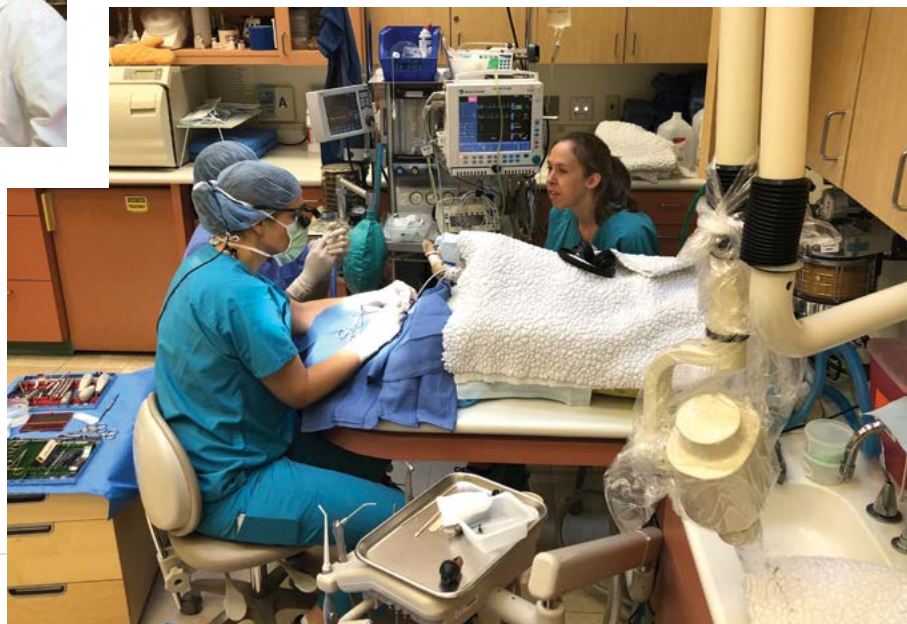Cutting-Edge Treatments

In addition to the more common teeth cleanings, extractions and root canal treatments, more advanced procedures performed by faculty and residents include tumor surgeries, the repair of mandibular and maxillofacial fractures, temporomandibular joint and cleft palate surgeries.

In 2012, Drs. Arzi and Verstraete began collaborating with engineers in BME to develop a tool to promote bone regrowth and allow for mandibular reconstructions after portions of jaws needed to be amputated due to injury or tumor removal. DOSS demonstrated that a regenerative approach to reconstruction of mandibular critical-size defects in dogs using a scaffold and growth factors such as bone morphogenic protein (rhBMP-2) can be performed successfully and represents an excellent functional solution. Starting with only small portions of one side of the jaw, the team is now able to reconstruct a complete arch of a dog's jaw. In the six years since the first surgery, national acclaim has brought patients from across the country, as the team has successfully regenerated the jaws of more than three dozen dogs.



Working with VIRC, the team discovered a stem cell treatment for FCGS. Patients like Lilly have seen chronic, debilitating mouth problems cleared after only a few treatments and stay cured for years, presumably forever. Lilly is now six years clear of the last signs of FCGS. When the clinical trial for the stem cell treatment was first implemented, it enrolled only cats that had gone through the accepted protocol of FCGS treatment—a full mouth extraction. Now the trial has progressed to include cats before extractions happen. To date, more than 30 cats have been successfully treated with the stem cell breakthrough. Seventy one percent of cats showed significant clinical improvement, and many cats demonstrated complete disease cure.





Advanced Technology

The use of computed tomography (CT scan) has become a vital component of most DOSS surgeries. The veterinarians compared the diagnostic benefits of conventional radiographs versus CT images of the skulls of dogs and cats with maxillofacial trauma. They determined that CT is superior to conventional skull and dental radiography for identification of anatomic structures and traumatic injuries in dogs and cats. While skull radiography is useful for visualizing the mandibular body and dental occlusion, CT allows for accurate assessment, diagnosis and treatment planning.

Cone-beam computed tomography (CBCT), the standard of care in human oral and maxillofacial diagnosis and treatment planning, is now being translated to veterinary medical care by DOSS. The UC Davis veterinary hospital is currently the only academic veterinary facility in the world that utilizes this technology. CBCT delivers high resolution images in two- and three-dimensional views, and allows for a more precise analysis of bone structure, tooth orientation and oral and maxillofacial disorders.

To make surgeries shorter, safer and more precise, DOSS has collaborated with BME to make exact 3D-printed replicas of patient skulls, derived from CT images. The exact dimensions enable clinicians to better prepare for surgeries by seeing the exact make-up and location of a defect, as well as using the skull to pre-measure and pre-fit plates that need to be utilized.

Training Future Specialists

There are currently 172 active diplomates (board-certified specialists) of the American Veterinary Dental College (AVDC). Many of them trained at UC Davis as part of the hospital's House Officer Program, the largest residency training program in the world. Under faculty supervision, residents gain in-depth knowledge of veterinary dentistry and oral surgery and its supporting disciplines.

The three-year residency program provides exceptional opportunities in advanced oral surgery and clinical research, giving residents access to the highest caseload of any teaching hospital, and the opportunity to participate in surgeries they would not see in other hospitals. Residents also gain

experience with the hospital's world-class imaging equipment and the corresponding consultations with radiologists.


"The quality of training that we receive is unparalleled due to our extensive caseload and exposure to a large number of complex surgical cases," said third-year resident Dr. Colleen Geisbush. "I feel fortunate to be part of a residency program that allows me to participate in surgeries that are not performed anywhere else in the world. Advanced procedures that residents in other programs may never perform begin to feel routine early on in our training."

Published Research

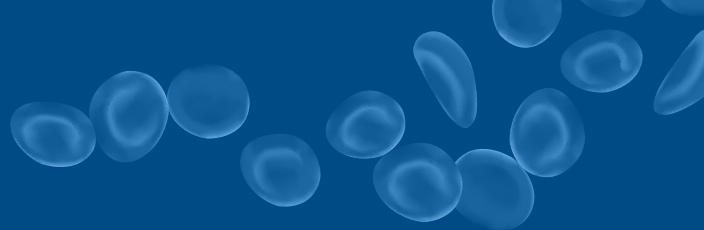
DOSS leads the way in published research, completing about ten research papers per year. Statistics from the AVDC reveal that the UC Davis dentistry team has produced two-thirds of all the research publications in the veterinary dental field. Recently, the team's research has been published in leading veterinary journals such as the *Journal of the American Veterinary Medical Association*, *Frontiers in Veterinary Science*, the *American Journal of Veterinary Research*, and *Stem Cells Translational Medicine*. Mainstream media coverage of DOSS' success has been garnered by the *New York Times*, *USA Today*, ABC News and many international outlets.

Drs. Verstraete and Milinda Lommer published the textbook *Oral and Maxillofacial Surgery in Dogs and Cats* in 2012, and it quickly became the foremost authority on veterinary oral maxillofacial surgery. This unprecedented resource is now present in virtually every clinic and hospital where veterinary oral surgery is performed. Barnes and Noble calls the book "indispensable for general practitioners with a dental and oral caseload."


As DOSS continues to be at the forefront of translational research, services and procedures offered at the UC Davis veterinary hospital continue to be on the rise. New research discoveries ultimately translate to new clinical applications, improving animal health and well-being.



Rare Blood Disorder Discovered in Cat



Miao Miao, a 4-year-old male domestic shorthair cat, was brought to the UC Davis veterinary hospital with persistent nosebleeds. Based on previous medical issues, his owners were aware that he had some variation of a blood platelet disorder (causing an inability to properly clot blood), but the exact make-up of that was never discovered. At UC Davis, specialists with the Internal Medicine Service ran a complete range of tests to attempt to discover the root of his bleeding issue. A complete blood count showed that Miao Miao was not anemic, had no evidence of inflammation, and had a normal platelet count. An ultrasound was also performed, which showed that Miao Miao had no evidence of bleeding into any of his other bodily cavities.



The team felt it was best to keep Miao Miao hospitalized for a few days to ensure he did not develop significant bleeding, and to discuss his case with other clinicians and researchers. Through a collaboration of UC Davis emergency, internal medicine, and research specialists, a unique cause to Miao Miao's bleeding was found.

Dr. Ronald Li, a critical care specialist with the UC Davis veterinary hospital's Emergency Room, operates a state-of-the-art platelet physiology laboratory with equipment and capabilities found in only a handful of veterinary centers around the world. By utilizing Dr. Li's laboratory equipment and expertise, Miao Miao's platelets were analyzed using state-of-the-art testing of his platelet function. Dr. Li discovered that Miao Miao has a congenital platelet disorder—Glanzmann thrombasthenia (GT)—that has never been reported in a cat. GT causes Miao Miao's platelets to be nonfunctional and lack expression of a protein called integrin, which is important for the formation of blood clot.

In humans and dogs, GT is caused by a genetic mutation in the genes responsible for making a platelet protein that is essential for clot formation. Dr. Li is currently analyzing Miao Miao's DNA to further characterize his genetic mutations. He hopes to identify the mutation so that cats with a similar bleeding disorder can be tested in the future.

Since Miao Miao is the first cat ever diagnosed with GT, there is currently no standard protocol of treatment. It will most likely continue to put him at risk of spontaneous bleeding the rest of his life. One method that has worked in similar cases is the use of Yunnan Baiyao. This Chinese herbal formula, which has antihemorrhagic effects, was popularized during the Vietnam War. Vietcong soldiers were known to carry the holistic medicine to stop the bleeding of wounds incurred during battle. Miao Miao's owners report it seems to be successful in treating his bleeding.

Dog Adapts to Tongue Amputation after Accident with Toy

Arai, a 5-year-old female pit bull terrier, loves to chew on balls. Her owners describe her as a “100 percent ball dog.” So when she had a ball in her mouth for a few hours, they didn’t think much was out of the ordinary. When Arai wouldn’t drop the ball when it was time to eat, however, they knew something was wrong.

The ball was constructed with one small circular opening, and her tongue was stuck so severely in the hole that her owners could not get it loose. The hole in the ball was only about one half inch in diameter, yet Arai’s tongue—average size for a 42-pound dog—managed to get sucked into the opening.

They took her to their local veterinary emergency room where Arai was sedated and the ball was cut off her tongue. After the ball was removed, her tongue was swollen due to a decrease in venous return from the region. She was treated with anti-inflammatory and antibiotic medications and was able to go home.

The next day, Arai was not eating or drinking, and her owners were only able to give her half of the prescribed dose of the anti-inflammatory drug and none of the antibiotic. They took her back to the veterinarian, who administered the drugs via injection.

When Arai’s tongue remained enlarged and turned dark purple the next day, her owners took her to the UC Davis veterinary hospital’s emergency room. There, emergency/critical care specialists consulted with Drs. Frank Verstraete and Boaz Arzi of the Dentistry and Oral Surgery Service, who advised that the front part of the tongue be amputated due to necrosis.

Arai was placed under general anesthesia and prepared for surgery by the Anesthesia/Critical Patient Care Service. Assisting Drs. Verstraete and Arzi was resident Dr. Colleen Geisbush, who removed the devitalized portion of Arai’s tongue—about three to four inches—using a surgical laser. After removal, the ends of the remaining healthy tongue were sutured together with absorbable sutures that dissolve on their own over the course of a few weeks. Arai recovered well from anesthesia and was able to go home that day.


Arai was fed a soft food diet while her tongue healed and may need to continue afterwards until she adapts to using her now shortened tongue. She continued on anti-inflammatory

medication, as well as antibiotics to help treat and prevent bacterial infection and a pain reliever.

Arai was kept away from any toys, bones, or anything hard to chew on during the next two weeks. Beyond warnings about toys with holes, her owners were also advised to only allow Arai to chew on soft toys—ones soft enough to indent with a fingernail. If a toy is harder than this (such as bones, antlers and sticks), they can cause tooth wear/damage, and potentially broken teeth. Frisbees and tennis balls can also cause tooth damage. (Visit the Veterinary Oral Health Council’s website [www.vohc.org] for suggestions on different treats and chews that can be offered to help prevent the progression of periodontal disease.)

Arai recovered quickly following surgery and has adapted well to new ways of eating, drinking and cleaning. Her owners report that she now “chomps” at the water instead of lapping it with her tongue. While it takes a bit longer to get enough water, she does well on her own. As for cleaning herself, she found a unique way to utilize the inside of her bottom lip.

At Arai’s 2-week, post-surgery recheck, Dr. Geisbush noted near complete healing of the surgical site and expected Arai to make a full recovery.





UC DAVIS
VETERINARY MEDICINE

(654W)
UC Davis Veterinary Hospital
c/o Office of the Dean—Advancement
School of Veterinary Medicine
University of California
One Shields Avenue
Davis, CA 95616-8734

Nonprofit Org.
U.S. Postage
PAID
Permit No. 3
Davis, CA

UC Davis School of Veterinary Medicine Ranked #1 in the World

Heartbeat is published by the School of Veterinary Medicine at the University of California, Davis: Dr. Michael D. Lairmore, dean; Hyemi Sevensing, assistant dean of advancement; Dr. Jane Sykes, chief veterinary medical officer; Tom Hinds, director of strategic planning and communications; Rob Warren, editor; Don Preisler, Carolyn Sawai, contributors. The University of California does not discriminate in any of its policies, procedures or practices. The university is an affirmative action/equal opportunity employer.



Stay Connected

To subscribe to *Heartbeat*, email your name and address to rjwarren@ucdavis.edu

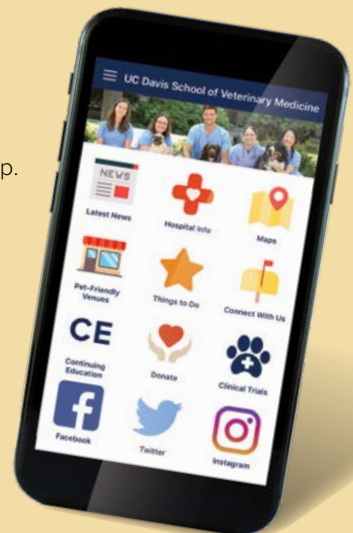
Please consider supporting UC Davis Veterinary Medicine give.ucdavis.edu/go/vmth



vetmed.ucdavis.edu/vmth

Vet Med App

Stay quickly connected to UC Davis Vet Med with our new mobile app. Download it at the Apple and Android app stores by searching "UC Davis Veterinary Medicine."



Equine Performance Center – Leading the Way in Equine Care

The Equine Performance Center will transform equine care with a new arena and gait analysis capability for lameness evaluations. Providing state-of-the-art force-plate and video analysis, this facility is one of the first projects planned for the comprehensive UC Davis Veterinary Medical Center. To learn more, visit www.vetmed.ucdavis.edu/giving/vmc or call us at 530-752-7024.

