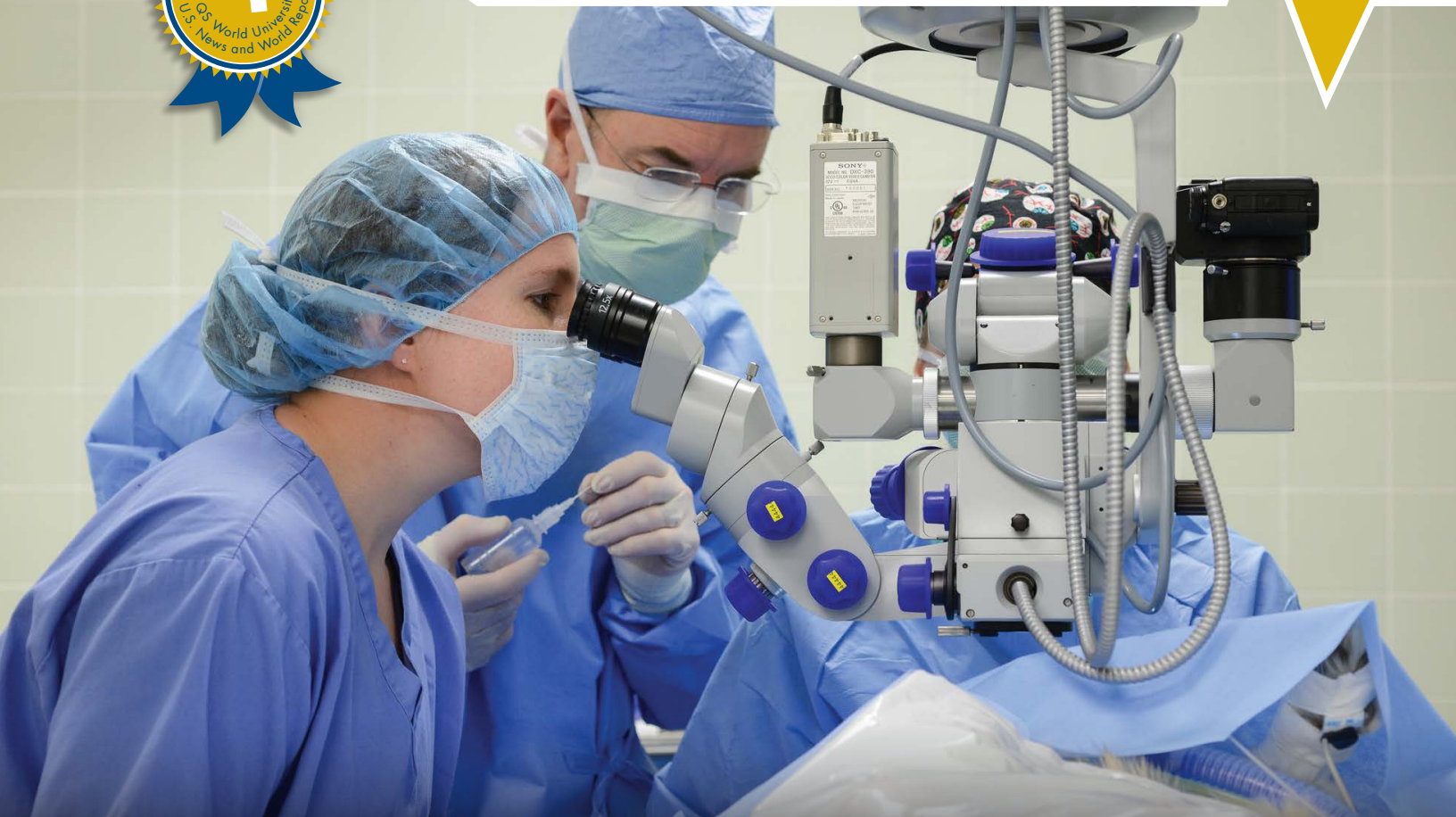



Research Translates to Cutting-Edge Treatments

For clients of the UC Davis veterinary hospital, one of the biggest advantages the hospital can offer is the ability for their animals to benefit from the vast research being conducted at the university. This research often translates into innovative procedures aimed at improving animal health or saving animals in dire situations. Many of these groundbreaking procedures are offered via the Veterinary Center for Clinical Trials, which seeks to advance patient care in a variety of disciplines, encompassing the wide array of services available in the hospital.

A current trial showing tremendous success is a new treatment for a debilitating oral disease in cats, feline chronic gingivostomatitis. The technique involves taking a cat's own fat-derived stem cells, processing and characterizing them, and then giving them back intravenously to reduce inflammation and promote tissue regeneration. The study also identified a potentially useful biomarker that could determine if cats will respond to stem cell treatment.

"We're the first researchers to come up with this patent-pending technique for any mammals, including humans," said Dr. Boaz Arzi of the Dentistry and Oral Surgery Service.

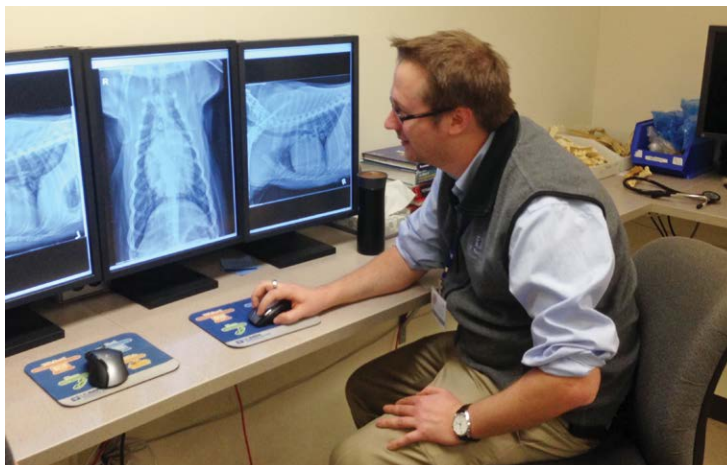
A recently completed clinical trial by Dr. Michele Steffey of the Soft Tissue Surgery Service led to an alternative treatment for nasal adenocarcinoma, a cancer in dogs' nasal cavities. This new approach to treating nasal tumors involves a minimally-invasive method of killing the tumor by freezing it with cryoprobes.

Beyond treating current conditions in clinical trials, other research studies can help in eliminating disorders in future generations of animals. Two recent studies were successful in leading to the creation of genetic tests that determine the possibility of subvalvular aortic stenosis in Newfoundlands (conducted by Dr. Joshua Stern and the Cardiology Service) and encephalopathy in Alaskan huskies (conducted by Dr. Karen Vernau and the Neurology/Neurosurgery Service)

For more information on clinical trials at UC Davis, please see www.vetmed.ucdavis.edu/clinicaltrials.

Don Low Fellowships Offer Unique Training Opportunities

The veterinary hospital annually offers advanced training opportunities for veterinarians through the Don Low/CVMA Practitioner Fellowship. The program provides 20 days of in-depth continuing education (CE) in a specialty service of the fellow's choice. The fellowship can be completed on a flexible basis, and earns the participant 72 hours of CE credits.



Dr. Tom Hansen reviews radiographs during his Don Low Fellowship with the Diagnostic Imaging Service.

"The chance to spend 20 days with the Small Animal Emergency and Critical Care Service was truly a once-in-a-lifetime opportunity," said Dr. Irene Fujishima Nakaoka. "The program is not just 20 days of observation – it's an opportunity to be at the forefront of veterinary medicine. It was the most intense and informative continuing education opportunity I have ever experienced as a veterinarian."

With the exponential expansion of discoveries and innovations in veterinary medicine, CE is the responsibility of every veterinary professional to keep current on the latest medical advances in diagnosis and therapy.

"The Don Low Fellowship allows a more in-depth and detailed approach to lifelong learning by immersion into a focused area of the fellow's choosing alongside faculty, staff, and students," said Dr. Karl Jandrey, director of the Center for Continuing Professional Education.


"I had an exceptional experience with the fellowship," said Dr. Ryan Goupil. "It was invaluable to see some of the advanced medical treatment options like mechanical ventilation and dialysis that are not available in my practice."

For Dr. Tom Hansen, currently completing a Don Low Fellowship with the Diagnostic Imaging Service, it has been a great opportunity for him to increase his skills in

small animal abdominal ultrasound and radiology. A former UC Davis DVM student, Dr. Hansen recalls working with past Don Low Fellows while he was a student. Just as it was when he was in school, the hospital's caseload plays a large part in the overall experience.

"One of the benefits of the program is the high and diverse caseload at the VMTH," said Dr. Hansen. "In a single day, you can see several different types of cases and species."

The fellowship—a joint activity between the school and the CVMA—is designed to meet practitioner needs not available within residencies or other advanced training programs. It is named after Dr. Donald G. Low (1925-2004), who served on the faculty from 1974-1991. For more information, please see www.vetmed.ucdavis.edu/ce.



Dr. Melissa Bain Wins AVMA Veterinarian of the Year

Dr. Melissa Bain, chief of the Behavior Service, was named the 2016 Bustad Companion Animal Veterinarian of the Year, as announced during the American Veterinary Medical Association's recent Veterinary Leadership Conference in Chicago. The award recognizes Bain's career long efforts to enhance the human-animal bond through research on companion animal behavior problems, enrichments for shelter animals and how different training methods affect dog behavior.

◀ Dr. Melissa Bain receives the 2016 Bustad Companion Animal Veterinarian of the Year award.

New Clinicians

Several hospital specialty services have added new clinicians in order to continue to provide the highest quality patient care. With more than 120 faculty veterinarians and more than 100 resident veterinarians, the UC Davis veterinary hospital has more clinicians than any hospital in the country.

Dr. Derek Cissell – Diagnostic Imaging Service

Dr. Cissell is a new assistant professor with the Diagnostic Imaging Service. He received his veterinary degree from the University of Pennsylvania in 2005, and completed a residency at UC Davis in 2011, as well as a PhD from UC Davis in 2015. Aside from his clinical duties, Dr. Cissell will be involved in teaching the DVM professional curriculum and will assist with training residents in the hospital. Throughout his career, he has published 12 peer-reviewed manuscripts, authored a book chapter, and recently completed a Comparative Medical Science Training Program grant funded by NIH.



Dr. Derek Cissell,
VMD, PhD, DACVR

Dr. Richard Pereira – Livestock Herd Health and Reproduction Service

Dr. Pereira joined the Livestock Herd Health and Reproduction Service as an assistant professor in late 2015. He received his veterinary degree from the Federal University of Uberlandia in Brazil. Dr. Pereira followed that with an internship at the University of Florida (2009), residency training



Dr. Richard Pereira,
BVSc, PhD

in Production Medicine at Cornell University (2011), and a PhD in Comparative Biomedical Sciences at Cornell (2015). He provides clinical veterinary herd health and reproduction services to beef, dairy, sheep, goat, and swine herds and flocks, as well as providing in-hospital clinical reproductive services and case management, including breeding soundness evaluation, pregnancy diagnosis, and management of fertility and infertility. Dr. Pereira's overall clinical and research interest is to promote livestock health through the development and promotion of a sustainable animal agriculture system that implements animal health and production practices that are efficient, environmentally sound, and economically feasible.

Dr. Michelle Giuffrida – Soft Tissue Surgery Service

Dr. Giuffrida recently joined the Soft Tissue Surgery Service as an assistant professor. She received her veterinary degree from the University of Pennsylvania in 2007. She completed a residency in surgery at Penn in 2011 and a fellowship in surgical oncology at the University of Florida in 2012.

Dr. Giuffrida received her Master of Science in Clinical Epidemiology (clinical trials track) in 2015. Her teaching experience has consisted primarily of clinical instruction of senior veterinary professional students and residents, which will continue at UC Davis. Dr. Giuffrida's areas of interest are in oncologic surgical disease and veterinary clinical trials methodology and design. She will be involved in teaching the DVM professional curriculum, graduate clinical training in the hospital, as well as faculty clinical duties.



Dr. Michelle Giuffrida,
VMD, DACVS

Dr. Bain was nominated by previous Bustad Companion Animal Award winner Dr. Benjamin Hart, UC Davis distinguished professor emeritus who mentored her while she served as a resident from 1998-2001. In nominating Dr. Bain, Dr. Hart described her as an “unquestionable leader in integrating the essence of the field of human-animal interactions with veterinary clinical behavior, animal welfare and the mental health of veterinarians.”

While serving her residency in clinical behavior under Dr. Hart's leadership, Dr. Bain was particularly attuned to the importance of the strong attachment and interaction

between her clients and patients. She believed that the field of clinical animal behavior was the closest recognized specialty in veterinary medicine that she could pursue relating to clinical medicine and the human-animal bond.

Dr. Bain is board-certified in both behavior and animal welfare, and serves as the director of professional student clinical education in the School of Veterinary Medicine. She is a past president of the American College of Veterinary Behaviorists and the American Veterinary Society of Animal Behavior.

Multitude of Equine Reproduction Services Available

With multiple board-certified reproduction specialists, the Equine Reproduction Service is available to provide routine and advanced reproductive care to patients at the hospital. The Service is experienced in breeding with fresh, chilled and frozen semen, and is adept at procedures such as embryo transfer, oocyte retrieval and intracytoplasmic sperm injection (ICSI).

Whether a maiden mare or an experienced broodmare, it is beneficial for every mare to be examined by an experienced equine veterinarian prior to breeding. UC Davis reproduction specialists can give mares thorough breeding soundness examinations, as well as discuss many other factors that could affect a mare's ability to conceive, such as proper nutrition, preventative medicine, parasite control and exercise. Although infertility or subfertility may occur because of pathological problems, management practices that influence the environment in which a mare lives can significantly affect her reproductive success.

The Service can also help clients with all aspects of reproductive wellness for stallions, as their potential productivity is just as important. The veterinarians will take into consideration the stallion's general health, soundness of musculoskeletal system (particularly the hind limbs), libido, reproductive system, and quality of the sperm.



The Equine Reproduction Service can assist with a multitude of breeding options.

Clinicians utilize advanced semen evaluation and processing techniques for subfertile stallions. The hospital also has capacity for semen freezing and storage onsite.

Based on their findings, the reproduction team can help owners determine the best course of action with which to proceed, including discussing breeding options (natural vs. artificial insemination), care during pregnancy and foaling options.

At foaling time, the Service can assist with any and all birthing needs. Whether it is for high-risk pregnancies or pregnancies anticipated to be normal, the hospital can keep a watchful eye on expecting mares to give owners peace of mind. Mares are personally monitored around the clock by a highly-trained veterinary technician staff, as well as by video monitoring and the Foal-Alert™ system. Foal-Alert™ devices are sewn into the vulva and activate when the mare goes into labor, allowing for veterinarians to immediately come to the scene. Should any complications arise, the hospital's board-certified surgeons and anesthesiologists are on call to assist with dystocias and C-sections. Post-foaling complications are handled by the hospital's world-class Neonatal Intensive Care Unit, headed by a board-certified critical care specialist.

To learn more about equine reproductive options at UC Davis, please contact the Equine Reproduction Service through the Large Animal Clinic at 530-752-0290.



San Diego Hosts Kidney Week Reception

The UC Veterinary Medical Center-San Diego (UCVMC-SD) recently hosted a reception for veterinarians and veterinary industry leaders who attended the American Society of Nephrology's Kidney Week in San Diego. Kidney Week, an annual conference for human and veterinary medical professionals, represents the largest and most prestigious gathering of the world's scientists, physicians, pathologists, and industry leaders with

◀ UCVMC-SD hosted veterinary renal medicine professionals during Kidney Week.

Thanks and Praise from Grateful Clients

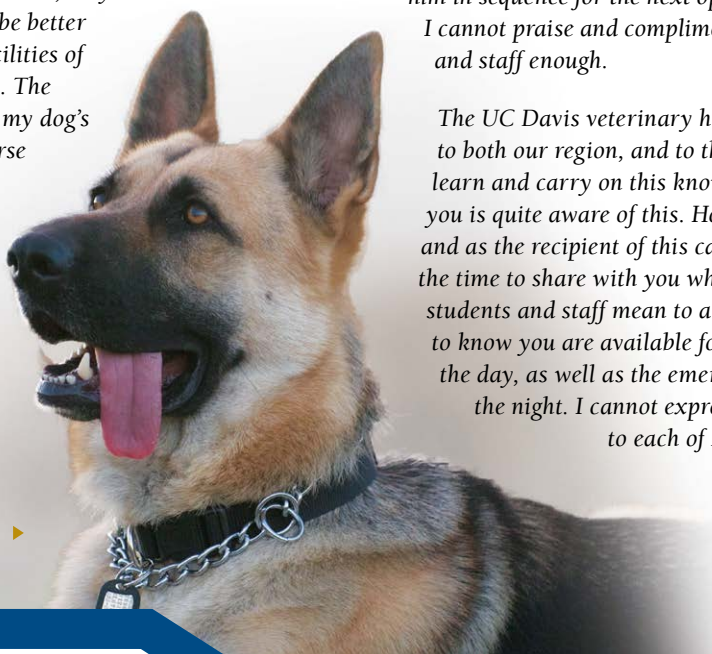
Dear UC Davis Veterinary Hospital,

Recently, my normally healthy and active German shepherd, Dunham, experienced a fibrocartilagenous embolism (small stroke in the spine) (FCE), which resulted in the almost immediate and complete paralysis of his left pelvic limb, and partial paralysis of the right one. He could not stand or walk with his hind legs. I rushed him to our local veterinarian, and after a two-hour wait to be seen by their on-duty veterinarian, realized Dunham's problem was above their capabilities. While waiting at that clinic, I had a phone consultation with the medical director of the local Pet Emergency Hospital, who advised me to get Dunham to UC Davis as soon as possible.

We arrived on campus shortly after midnight, and were met in the parking lot by your emergency veterinarian, Dr. Mara Senzolo, as well as technician Lori Weston and student Carin Stevens. After administering a physical and neurological exam, your staff made the decision to bring in the on-call neurologists, Drs. Bev Sturges and Shannon Kerrigan, for further examination and determination if he would require immediate surgery. By 2:30 a.m., they determined Dunham was stable, and it would be better for him to wait until morning when the full facilities of the hospital would be available to care for him. The neurologists were very thorough in explaining my dog's condition, the probable cause and the best course of action that would be taken in his care. Dunham spent the remainder of the night in your neurology ward under observation and on fluids. As he was quite anxious and confused, your technician spent the majority of the night with him in his kennel to comfort him and make sure he was okay.

In the morning, after another full physical and neurological exam, Dr. Jessica Rivera and

Dunham is recovering thanks to the hospital's ►
dedicated overnight and on-call team.



student Liz Lee contacted me and informed me of their probable finding that Dunham most likely did experience an FCE, and in order to be sure, an MRI would be indicated. Dr. Rivera was able to work Dunham into an already full MRI schedule, and the MRI was conducted that afternoon. The MRI showed a lesion inside Dunham's spinal cord consistent with an FCE. While at the hospital, Dunham's condition improved, and he was discharged the next morning. Each day since, he has been substantially improving, regaining increasing control and balance of his left pelvic limb. Today he is back at an almost 95% pre-onset state.

While the events I described above are most likely routine and "another day in the life" for your facility, its students and staff, they were far from it for me. My dogs are my family and their care and wellbeing is paramount. The knowledge, professionalism and compassion that each of your students and staff showed was immense. Dr. Rivera took several hours out of her full schedule to answer every one of my questions, fully explain my dog's condition, the likely cause and his probable prognosis. I feel she went above and beyond to fit him into the MRI schedule rather than merely place him in sequence for the next opening three days later. I cannot praise and compliment her and the students and staff enough.

The UC Davis veterinary hospital is a fine facility to both our region, and to the students who wish to learn and carry on this knowledge. I believe each of you is quite aware of this. However, in this instance, and as the recipient of this care, I wanted to take the time to share with you what your facility, your students and staff mean to a client. It is comforting to know you are available for the routine care during the day, as well as the emergencies in the middle of the night. I cannot express my gratitude enough to each of Dunham's caregivers.

Very respectfully,
Todd C., Fresno, CA

an interest in kidney disease. Kidney Week was attended by more than 13,000 professionals, showcased more than 1,500 state-of-the-art presentations, and featured thousands of posters and abstracts probing advances for a better understanding of kidney disease.

Historically, veterinarians with an interest in kidney disease have not prioritized the opportunities afforded by the breadth and quality of Kidney Week to the advancement of managing kidney disease in animals. This reception provided

a mechanism to publicize these opportunities, as well as an incentive and source of camaraderie for veterinary clinicians and scientists to gather at this important meeting.

This was the fourth reception in a tradition for UCVMC-SD when Kidney Week is held in San Diego. UCVMC-SD, a satellite of the UC Davis veterinary hospital, offers services in renal medicine, cardiology, pharmacy, and nutrition. Led by Dr. Larry Cowgill, the center has been offering world-class veterinary services to Southern California pet owners since 2002.

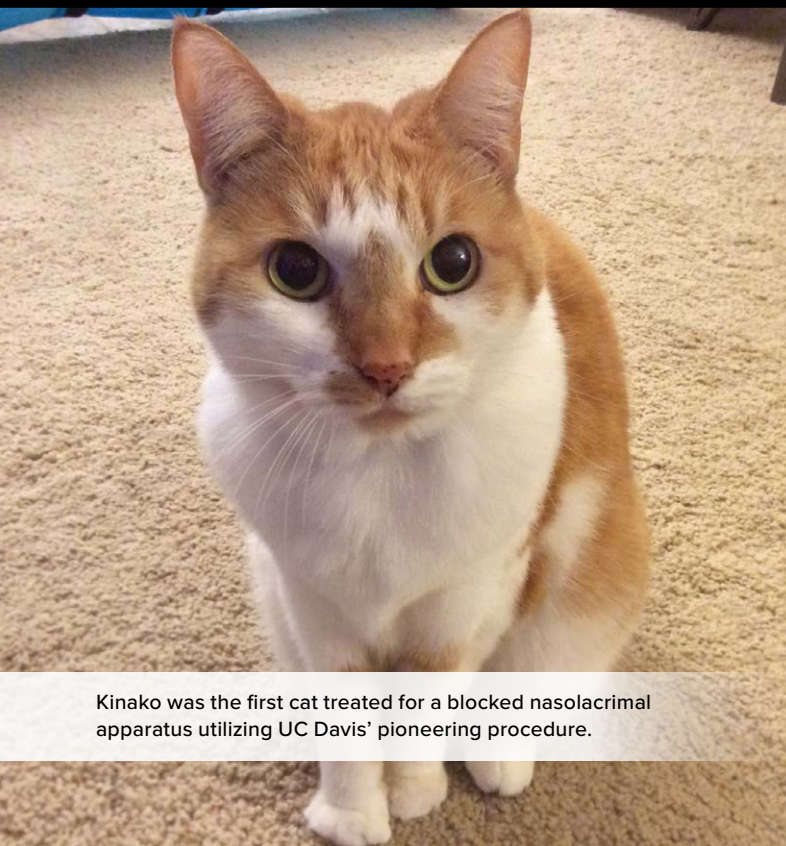
UC Davis' Pioneering Nasolacrimal Endoscopy & Stenting Procedure Successful in First Cat

Kinako, an 8-year-old female domestic shorthair cat, was continually troubled with build-up of tears in her left eye, sometimes resulting in infections. Her owner took her to see their veterinarian, who attempted to flush the tear duct of that eye several times, but to no avail. While the situation was not life threatening, Kinako's owner did not want her to suffer needlessly for the rest of her life. Kinako's veterinarian suggested taking her to see the specialists in the Ophthalmology Service at the UC Davis veterinary hospital.

Drs. David Maggs and Ann Strom suggested that if a CT scan revealed an obstruction in Kinako's tear duct, then she undergo a new procedure pioneered at UC Davis to permanently reopen the duct. This new, minimally invasive approach to nasolacrimal obstructions had already shown great promise in one horse and a number of dogs, but had not

Thanks to advances in equipment and technique, a multidisciplinary team of clinicians from UC Davis are now having unprecedented success treating NLA blockages.

JANUARY CASE OF THE MONTH – KINAKO



Kinako was the first cat treated for a blocked nasolacrimal apparatus utilizing UC Davis' pioneering procedure.

yet been performed in a cat. The lacrimal system is responsible for the generation and drainage of tears. The drainage portion of the system consists of several important structures collectively known as the nasolacrimal apparatus (NLA). This frequently becomes blocked and sometimes infected, leading to discomfort, tear staining and discharge from the eye, resulting in skin inflammation. However, the NLA is made up of such small ducts that access to the obstruction can be extremely difficult.

Thanks to advances in equipment and technique, a multidisciplinary team of clinicians from UC Davis' Ophthalmology, Internal Medicine, Soft Tissue Surgery, Anesthesia, and Diagnostic Imaging Services are now having unprecedented success treating NLA blockages.

With cameras now small enough to fit into the tiny drainage ducts, clinicians utilize endoscopy (as well as CT and fluoroscopy) to identify and bypass or remove NLA obstructions. Whether the obstructions are caused by a scarred duct or a foreign body, temporary stents can usually be placed so as to reopen the duct from eye to nose.

As they had done before for the equine and canine patients, the UC Davis team came together to successfully unobstruct and temporarily stent Kinako's left nasolacrimal passage. Following the surgery, the stent was left in place for two months to allow adequate time for the duct to heal in an open position. Although Kinako initially had some persistent ocular discharge caused by an infection in the tissue around the eye, this cleared with antibiotics, and Kinako's left eye no longer shows signs of build-up or excessive tearing, and her nasolacrimal duct remains clear.

About three months following surgery, Kinako's owner reported that her left eye demonstrated what he defined as a complete resolution of signs.

To date, UC Davis has treated 15 dogs, two cats, and one horse with this pioneering procedure that now offers a minimally invasive alternative for referring veterinarians who have been faced with treating NLA obstructions using conventional, more invasive and typically less successful methods.

Importantly, many of the cases referred were considered particularly challenging since they were referred to UC Davis by local ophthalmologists who were unable to treat them using conventional methods. Because of this initial success, general practitioners and ophthalmology specialists are recognizing UC Davis' unique approach to effectively treat this condition, and a clinical trial is underway at the veterinary hospital to evaluate the procedure so that this can become the standard-of-care for this otherwise frustrating disease complex.

UC Davis Veterinary Oral Surgeons Repair Dog's Crushed Skull

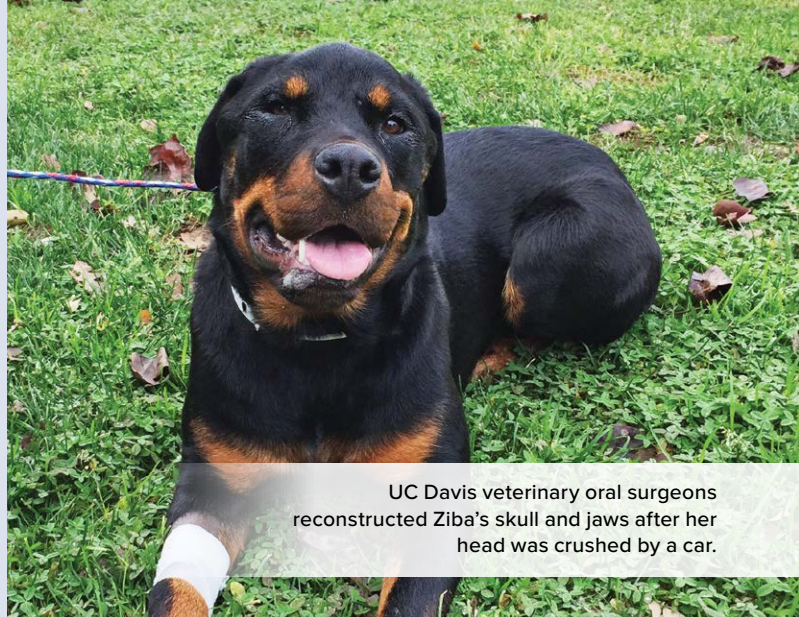Ziba, an 8-month-old female Rottweiler, was accidentally hit by a car and suffered extensive injuries to her head four months ago. Her skull and jawbones were fractured in several areas, and brain damage was feared. Thanks to surgeons at the UC Davis veterinary hospital, however, she is on the road to recovery, and her outlook is promising.

Like all maxillofacial trauma cases brought to UC Davis, Ziba was seen by the Dentistry and Oral Surgery Service (DOSS). While she was alert and responsive, Ziba had a sunken appearance to her right eye, a clear misalignment of her jaws, generalized facial swelling, was bleeding and had decreased airflow from both nostrils, had blood-tinged saliva from the mouth, and had an increased effort to breathe with loud snorting sounds. Cerebrospinal fluid was also leaking from her nostrils, a clear indication of potential brain damage and a reflection of the severity of the trauma. Even if Ziba's skull fractures could be repaired, the potential brain damage could lead to secondary systemic problems like seizures or diabetes throughout her life.

Initial CT scans from her referring veterinarian determined many fractures to her skull, coupled with brain swelling and a lack of oxygen to the brain. As with all catastrophic head injuries, DOSS consulted with the hospital's Ophthalmology and Neurology Services to examine for further damage. Luckily, Ziba had relatively few neurological abnormalities given the extent of her injuries – the biggest exception being that her right optic nerve was compromised, which ophthalmologists determined was causing blindness in her right eye.

The hospital's Diagnostic Imaging Service was also brought in to perform further skull CT scans, as well as thoracic and abdominal radiographs. The radiographs revealed no evidence of thoracic or abdominal cavity trauma. The CT, however, revealed to true extent of the damage to her head: numerous maxillofacial and bilateral mandibular fractures, C1 vertebra fracture, depressed fractures of the brain case, mild intracranial hemorrhage, partial dislocation and fracture of the right temporomandibular joint (TMJ), changes to the bones of her hyoid apparatus (which holds the larynx in place and supports the pharynx and tongue) and the neck muscles that support it, and complicated crown root fractures of the right upper fourth premolar and first molar teeth.

Due to Ziba's young age and current overall condition, DOSS determined that reconstructive maxillofacial surgery was possible, and she could recover with proper follow-up treatment. The Anesthesiology Service prepared Ziba for surgery (and would continue to play an important role in management of pain throughout her stay). The nearly five-hour surgery was performed by DOSS faculty members,



FEBRUARY CASE OF THE MONTH – ZIBA

assisted by resident veterinarians and dedicated staff. The team's reconstruction of Ziba's skull, jaws and TMJ involved closing the fractures with specialized titanium mini-plates and screws which were contoured and placed to reestablish the normal anatomy of the bones and joints.

Following surgery, a large gauge wire was placed around Ziba's bottom jaw, behind her canine teeth, in order to align her two mandibles to facilitate appropriate healing. The team also bonded her upper and lower canine teeth together on each side with a specialized biocompatible restorative composite to achieve a temporary maxillary-mandibular-fixation, which allowed the fracture of her TMJ and other mandibular bones time to heal. Ziba recovered in the Intensive Care Unit, where she remained overnight and received individualized postoperative monitoring and care.

Two weeks following the surgery, Ziba returned to UC Davis for suture removal and an ophthalmic examination. Unfortunately, the blindness in her right eye persisted and appeared to be permanent. As she had been since the surgery, Ziba was to remain on strict crate rest and be fed through a tube.

A month later, she returned for another follow-up examination where veterinarians removed the composite and wiring, as well as the two fractured molar teeth. Ziba was able to successfully eat food by her mouth for the first time since the injury. She remained on crate rest, but was allowed short walks.

In another two weeks, Ziba's condition improved enough for her to start utilizing soft chew toys to exercise her jaws and joints. Finally, three months post-surgery, a CT scan of Ziba's skull showed that the fractures were healing appropriately, and there is no evidence of implant failure or infection. Although there may be potential long-term issues associated with the trauma, Ziba's veterinary care team is pleased with her progress and hope for many years ahead.

Did You Know?

... that Delaina Matz is the new After Hours Client Services Manager? Delaina has been a Client Services team member for the past fifteen years and worked in both the Large and Small Animal Clinics. Most recently, Delaina has worked in the accounts receivable area, assisting owners that may have financial concerns or qualify for supplemental funding. Delaina's extensive knowledge of the hospital along with her dedication and commitment to our patients and clients while providing excellent service quickly identified her as the top candidate. Congratulations, Delaina!

... that surgery resident Dr. Kathryn Pitt recently won an award at the 2016 American College of Veterinary Surgeons Surgery Summit? At the national gathering of veterinary surgeons, Dr. Pitt won a Poster Presentation Award for her study of "Laparoscopic Adrenalectomy for Removal of Unilateral Noninvasive Pheochromocytomas in Dogs."

... that public tours of the hospital are available? The 90-minute tours must be booked in advance by calling 530-752-1507.



Dr. Kathryn Pitt with her award-winning poster.



Featured Clinical Trial

Dr. Michael Kent is recruiting for a new clinical trial for dogs diagnosed with osteosarcoma. The trial focuses on finding a way to slow or stop the spread of the tumor to the lungs. Owners are encouraged to enroll any dog diagnosed with or strongly suspected of having osteosarcoma in the pelvis or one of the legs. For more information about this and other groundbreaking trials, visit www.vetmed.ucdavis.edu/clinicaltrials or email vetcintrials@ucdavis.edu

CE Calendar

Veterinary Continuing Education

(530) 752-3905, Fax: (530) 752-6728, tweddale@ucdavis.edu

Upcoming Veterinary Continuing Education Events:

- March 16-19 IRIS Renal Week, UC Davis
- April 9-10 Wildlife and Exotic Animal Symposium, UC Davis
- May 21-22 Beginning Practical Ultrasound, UC Davis

For more information on these and other upcoming CE events, please visit www.vetmed.ucdavis.edu/ce.

Connect with us

For Appointments Call:

Small Animal Clinic: (530) 752-1393

Large Animal Clinic: (530) 752-0290



Like us on Facebook

<https://www.facebook.com/ucdavisvetmed>



Watch us on YouTube

<http://www.youtube.com/ucdvetmed>



Follow us on Twitter

<http://twitter.com/ucdavisvetmed>



Follow us on Instagram

<https://www.instagram.com/ucdavisvetmed>

www.vetmed.ucdavis.edu/vmth

To subscribe to VMTH Heartbeat, email rjwarren@ucdavis.edu

Please consider supporting UC Davis Veterinary Medicine
https://secure.vetmed.ucdavis.edu/public/E_Gifts_vm